

Osteosarcoma with metastatic disease at presentation, surgical management: two cases report

Merino-Rueda, Luis Rodrigo^{1*}, Mellado-Romero, María Ángela¹, Díaz-Martín, Andrés¹ and Ramos-Pascua, Luis Rafael^{1,2}

¹Department of Orthopaedic Surgery, Hospital Universitario 12 de Octubre, Madrid, Spain

²Department of Surgery, Complutense University of Madrid, Spain

Abstract

Osteosarcoma is the most common primary sarcoma of bone, most of them occurring in adolescents. Around 15% and 30% of patients with malignant bone tumors present with metastatic disease at the time of diagnosis. There is limited evidence on the best therapeutic strategy in these patients.

We report two cases of osteosarcoma of the proximal femur in patients with metastatic disease at diagnosis, who were treated surgically and evaluated their evolution throughout follow-up and review the main literature on this complex disease.

Background

Osteosarcoma is the most common primary sarcoma of bone, most of them occurring in adolescents [1,2]. Around 15% and 30% of patients with malignant bone tumors present with metastatic disease at the time of diagnosis [1, 3-6], which badly influences the prognosis of these patients. Five-year survival rates decrease from 70% to 8-35% in metastatic disease [3,5,7-13].

Because the treatment of these patients depends on many factors such as prior quality of life, metastatic number and site [3,14] and resectability of the primary lesion among others, there is limited evidence on what is the best strategy in these patients. There are few reported cases of the surgical treatment of the primary lesion in these patients.

We report two cases of osteosarcoma with metastatic disease, which were treated surgically and evaluate their evolution throughout follow-up.

Case presentation

Case report 1

A 15-year-old male with a free medical history was evaluated at our center in February 2018. He was complaining of right hip pain that extends through the knee and limp for the previous 4 months. There was no history of significant trauma. The patient complained of sharp pain, also at night, that wasn't relieved with painkillers. At the moment of consultation, he also presented pain at rest. On clinical examination, there was touch tenderness in the groin area and the range of internal rotation of the hip was limited.

Anteroposterior and axial radiographs of the left hip showed a sclerotic lesion with continuous periosteal reaction at the femoral neck (Figure 1). The MRI examination showed a lesion with osteoid matrix affecting the apophyseal, metaphyseal and proximal diaphyseal region of the right femur, with soft tissue component, suggestive of osteosarcoma (Figure 2).

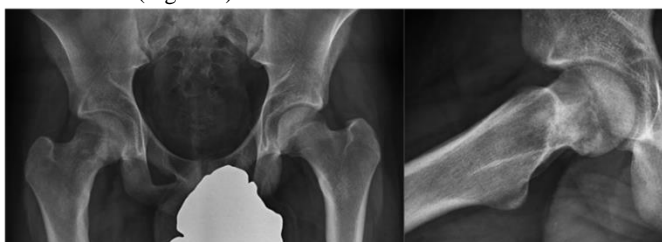

Figure 1: X-ray of the right femur showing a sclerotic lesion with continuous periosteal reaction at the level of the femoral neck.

CT guided core needle biopsy of surrounding soft tissue was performed. The microscopic examination reported an osteoblastic osteosarcoma. The PET scan (Figure 3) revealed a lesion with increased uptake in the right acetabulum, and two lesions in the right and left lower lung lobes, which were not present on the first body CT scan. The patient was diagnosed with stage IV osteosarcoma and started chemotherapy treatment according to the EURAMOS-1 2011 protocol [15], methotrexate, cisplatin and adriamycin.

In March, the hip pain increased sharply. A new X-ray was

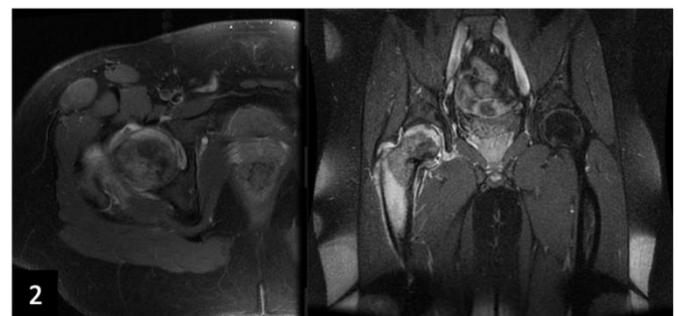


Figure 2: Figure 2: MRI with osteogenic lesion in proximal femur with cortical rupture and soft tissue mass.

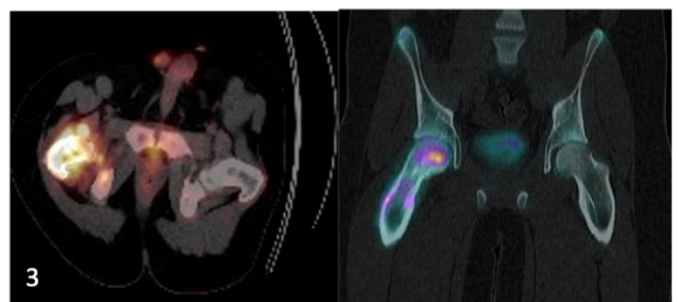


Figure 3: PET scan. A lesion with increased uptake is observed in the right acetabulum and two lesions in the right and left lower pulmonary lobes.

performed which showed an intracapsular hip fracture. The fracture was treated by closed reduction and percutaneous osteosynthesis with 4 cannulated screws (Figure 4). After three weeks the patient resumed his chemotherapy treatment.

Primary tumor surgery was accomplished in June 2018 (Figure 5). A wide margin resection of Enneking II and partially III zone was carried out associated with extraarticular proximal hip resection. Reconstruction was performed with Ice-Cream Cone prosthesis, dual mobility cup and femoral megasystem-C prosthesis by Link, without any early complication.

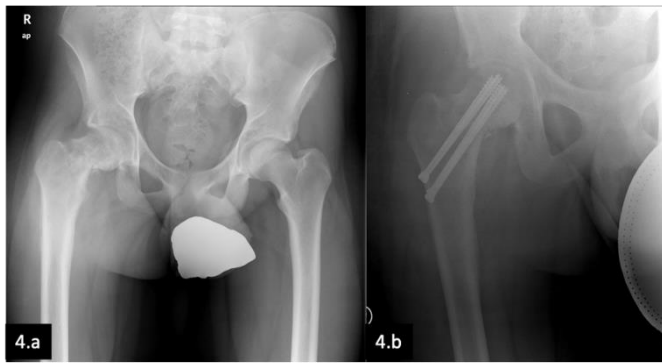
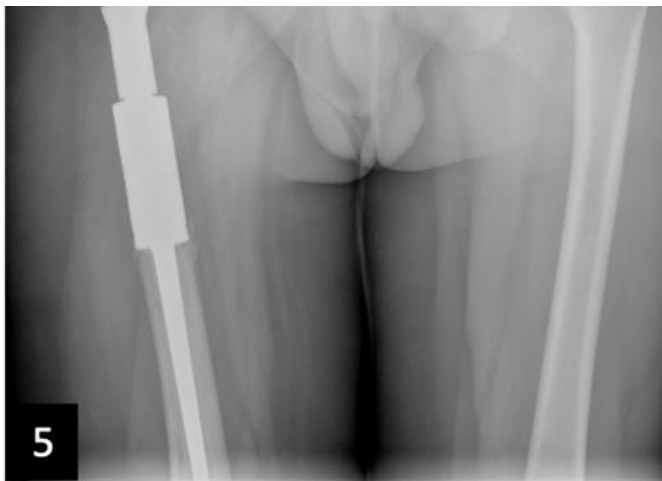


Figure 4: 4.a. Pathological fracture of the femoral neck.

4.b. Postoperative radiograph, osteosynthesis with three cannulated screws.

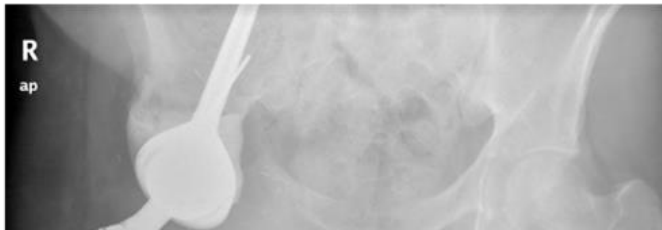

Figure 5: Postoperative pelvis x-ray. Replacement of the proximal femur and acetabulum with a megaprosthesis.



In September 2018, the patient was restaged, observing only 5 nodules smaller than 4 mm in the right lung. The multidisciplinary sarcoma team decided on surgical management of metastatic lung disease. On microscopic study, malignant evidence was noticed only in 1 of the nodules.

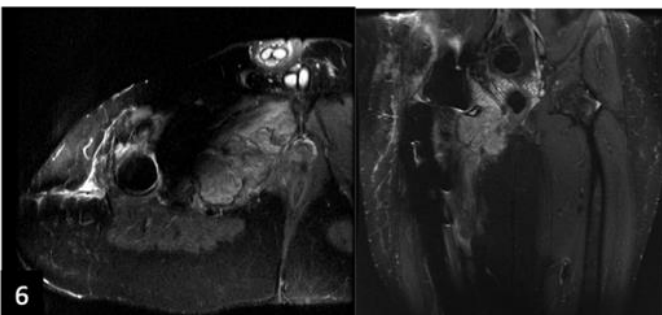


Figure 7: Antero-posterior and axial x-ray of the left hip showing permeative lesion with sclerotic matrix and discontinuous periosteal reaction.

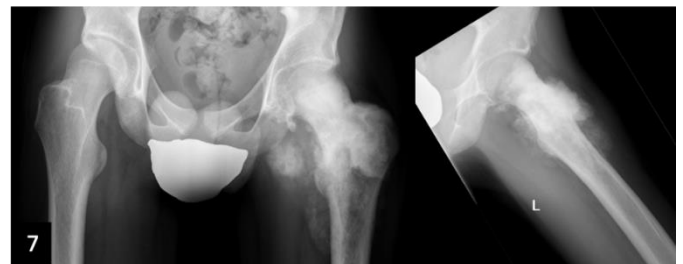


Figure 8: MRI examination showed a proliferative lesion with a large soft tissue mass compatible with the diagnosis of osteosarcoma of the proximal femur.

Thoracic-abdominal CT scan (Figure 9) revealed lymphatic and pulmonary metastasis. There were hilar and mediastinal lymph nodes and multiple, bilateral, pulmonary nodules. CT guided core needle biopsy was performed. The microscopic examination reported an osteogenic sarcoma.

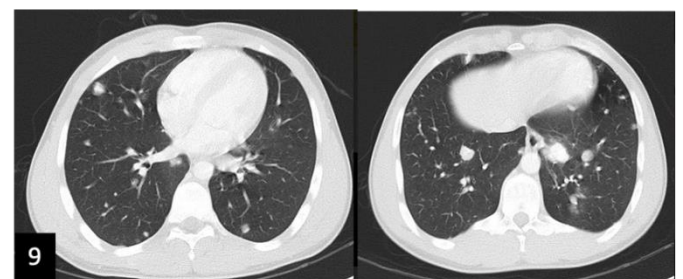


Figure 9: Thoracic-abdominal CT scan showed pulmonary metastasis.

The patient finished chemotherapy in January 2019. Restaging evaluation imaging showed local recurrence in pubic bone and surrounding soft tissue (Figure 6), with no systemic dissemination, so that another surgery was done. Resection of left bone up to contralateral pubic bone was attempted but infiltrated tissue was friable and surrounding adjacent to femoral neurovascular bundle, R2 resection was done.

The patient started chemotherapy according to EURAMOS-1 2011 protocol [15] based on methotrexate, cisplatin and adriamycin. After 10 weeks of treatment, restaging showed partial primary tumor response and similar lymphatic and pulmonary lesions. The patient finished chemotherapy in March 2019. Multidisciplinary team for primary bone cancer disposed of surgical management or primary tumor, as the size of the tumor had decreased and limb-salvage surgery could be done, and ongoing second line chemotherapy with gemcitabine and docetaxel.

Primary tumor surgery was accomplished in June 2019 (Figure 10). A wide margin resection of proximal femur was carried out. Reconstruction was performed with dual mobility cup and femoral, cemented, megasystem-C prosthesis by Link with soft tissue adhesion to trevira tube.

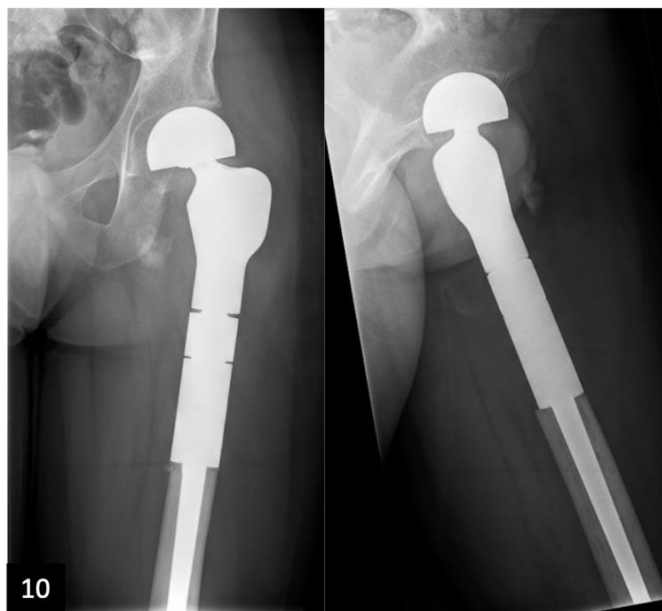

Figure 10: Postoperative pelvis x-ray. Replacement of the proximal femur with a megaprosthesis.

In January 2020, he complained of aggravated hip pain and swollen thigh, probably after a forceful twist. Dislocation of tumoral prostheses was seen on simple x-ray. The patient had an urgent surgery with open reduction of dislocation, since closed reduction was unsuccessful. Trevira tube was interposed between the acetabulum and the cup. Stable reduction was achieved.

Restaging protocol imaging after finishing chemotherapy in May 2020 revealed no local recurrence. Besides, it was discovered brand new pleural nodules, two of them over 3 cm long. In September 2020, according to the multidisciplinary team, resection of both nodules was accomplished, and second line chemotherapy was carried on.

During the next following months, the patient had multiple admissions to the hospital because of tumoral and infectious pleural effusion. Despite executing pulmonary radiation therapy, the patient continued with multiple pleural effusions and enlarged pulmonary and pleural nodules. Effusion evacuation and pleurodesis with doxycycline was done. Nowadays, the patient is alive, awaiting for response for new chemotherapy clinical trials.

Discussion

Debate has been going on about the best clinical management of patients with metastatic disease at presentation in bone sarcomas. It is clear that early-stage disease is best handled with surgical resection of primary tumor and adjunct treatment as chemotherapy, which have good survival rates up to 70% [3,5,7-12]. However, the strategy for metastatic disease remains a matter of debate [3,16].

There is not enough evidence regarding what medical treatment could improve survival. As per NCCN Clinical Practice Guidelines in Oncology for bone cancers 2018 [6], chemotherapy is recommended for all patients regardless of the status of surgical margins and the time for chemotherapy should be between 28 to 49 weeks following wide excision. Recently, Malik *et al.* [17] analyzed the United States National Cancer Database to answer this question. As the authors remark, quality-of-life wasn't taken into account as well as the number and location of metastases were not differentiated in the database. In line with other studies [3,13,18,19], they showed that surgical resection of primary tumors improved survival rates, regardless of resection or not of metastatic sites.

After multivariate regression analysis, the authors could not observe an independent survival benefit for resection of metastases, probably because of the biases mentioned. On the other hand [20] showed that combination with surgical resection of pulmonary metastases substantially improved overall survival, as recommended by other authors [16]. The consensus view of most articles [14,17,20] is that aggressive chemotherapy and surgical removal of primary tumors helps to improve survival.

Aside from all these studies, the results may be limited by a lack of generalizability. These findings may be helpful for decision making, but treatment of these patients should always be decided in multidisciplinary groups, based on individual characteristics, location of lesion and resectability [16].

Conclusion

In this work, we have reported two cases of metastatic osteosarcoma. Improved treatment modalities have led to an increase in the survival rate of primary and secondary lesions in patients with osteosarcoma.

A multimodality treatment approach including induction chemotherapy followed by surgical resection and postoperative radiotherapy was planned for these cases. The consensus opinion of most authors [14,17,20] is that aggressive chemotherapy and surgical removal of primary tumors help improve survival.

Acknowledgements

We thank our colleagues in the musculoskeletal oncology team for their collaboration in the final result of the article.

Conflict of Interest

Nothing to declare

References

1. Miller BJ, Cram P, Lynch CF, Buckwalter JA. Risk factors for metastatic disease at presentation with osteosarcoma: an analysis of the SEER database. *J Bone Joint Surg Am.* 2013; 3; 95: e89.
2. Mirabello L, Troisi RJ, Savage SA. Osteosarcoma incidence and survival rates from 1973 to 2004: data from the Surveillance, Epidemiology, and End Results Program. *Cancer.* 2009; 115: 1531-43.
3. Mialou V, Philip T, Kalifa C, Perol D, Gentet JC, et al. Metastatic osteosarcoma at diagnosis: prognostic factors and long-term outcome--the French pediatric experience. *Cancer.* 2005; 104: 1100-9.
4. Marko TA, Diessner BJ, Spector LG. Prevalence of Metastasis at Diagnosis of Osteosarcoma: An International Comparison. *Pediatr Blood Cancer.* 2016; 63: 1006-11.
5. Kaste SC, Pratt CB, Cain AM, Jones-Wallace DJ, Rao BN. Metastases detected at the time of diagnosis of primary pediatric extremity osteosarcoma at diagnosis: imaging features. *Cancer.* 1999; 86: 1602-8.
6. Bacci G, Ferrari S, Longhi A, Forni C, Zavatta M, et al. High-grade osteosarcoma of the extremity: differences between localized and metastatic tumors at presentation. *J Pediatr Hematol Oncol.* 2002; 24: 27-30.
7. Harris MB, Gieser P, Goorin AM, Ayala A, Shochat SJ, et al. Treatment of metastatic osteosarcoma at diagnosis: a Pediatric Oncology Group Study. *J Clin Oncol.* 6: 3641-8.
8. Marina NM, Pratt CB, Rao BN, Shema SJ, Meyer WH. Improved prognosis of children with osteosarcoma metastatic to the lung(s) at the time of diagnosis. *Cancer.* 1992; 70: 2722-7.

9. Meyers PA, Heller G, Healey J, Huvos A, Lane J, et al. Chemotherapy for nonmetastatic osteogenic sarcoma: the Memorial Sloan-Kettering experience. *J Clin Oncol.* 1992; 10: 5-15.
10. Damron TA, Ward WG, Stewart A. Osteosarcoma, chondrosarcoma, and Ewing's sarcoma: National Cancer Data Base Report. *Clin Orthop Relat Res.* 2007; 459:40-7.
11. Ottaviani G, Jaffe N. The epidemiology of osteosarcoma. *Cancer Treat Res.* 2009; 152:3-13.
12. Smeland S, Bielack SS, Whelan J, Bernstein M, Hogendoorn P, et al. Survival and prognosis with osteosarcoma: outcomes in more than 2000 patients in the EURAMOS-1 (European and American Osteosarcoma Study) cohort. *Eur J Cancer.* 2019; 109: 36-50.
13. Bacci G, Rocca M, Salone M, Balladelli A, Ferrari S, et al. High-grade osteosarcoma of the extremities with lung metastases at presentation: treatment with neoadjuvant chemotherapy and simultaneous resection of primary and metastatic lesions. *J Surg Oncol.* 2008; 98: 415-20.
14. Meyers PA, Heller G, Healey JH, Huvos A, Applewhite A, et al. Osteogenic sarcoma with clinically detectable metastasis at initial presentation. *J Clin Oncol.* 1993; 11: 449-53.
15. Whelan JS, Bielack SS, Marina N, Smeland S, Jovic G, et al. EURAMOS-1, an international randomised study for osteosarcoma: results from pre-randomisation treatment. *Ann Oncol.* 2015; 26: 407-414.
16. Meazza C, Scanagatta P. Metastatic osteosarcoma: a challenging multidisciplinary treatment. *Expert Rev Anticancer Ther.* 2016; 16: 543-56.
17. Malik AT, Alexander JH, Mayerson JL, Khan SN, Scharschmidt TJ. Is Surgical Resection of the Primary Site Associated with an Improved Overall Survival for Patients with Primary Malignant Bone Tumors Who Have Metastatic Disease at Presentation? *Clin Orthop Relat Res.* 2020; 478: 2284-2295.
18. Aljubran AH, Griffin A, Pintilie M, Blackstein M. Osteosarcoma in adolescents and adults: survival analysis with and without lung metastases. *Ann Oncol.* 2009; 20: 1136-41.
19. Goorin AM, Delorey MJ, Lack EE, Gelber RD, Price K, et al. Prognostic significance of complete surgical resection of pulmonary metastases in patients with osteogenic sarcoma: analysis of 32 patients. *J Clin Oncol.* 1984; 2: 425-31.
20. Bacci G, Mercuri M, Briccoli A, Ferrari S, Bertoni F, et al. Osteogenic sarcoma of the extremity with detectable lung metastases at presentation. Results of treatment of 23 patients with chemotherapy followed by simultaneous resection of primary and metastatic lesions. *Cancer.* 1997; 79: 245-54.

***Correspondence:** Dr. Merino-Rueda, Luis Rodrigo, Department of Orthopaedic Surgery, Hospital Universitario 12 de Octubre, Madrid, Spain, E-mail: rodrigomerinorueda@gmail.com

Received: 6 Nov 2021; **Accepted:** 25 Nov 2021; **Published:** 5 Dec 2021

Citation: Luis Rodrigo MR, María Ángela MR, Andrés DM, Luis Rafael RP. Osteosarcoma with metastatic disease at presentation, surgical management: two cases report. *Surg Case Rep Image.* 2021; 1: 105.

Copyright: © 2021 Luis Rodrigo MR. This is an open-access article distributed under the terms of the Creative Commons Attribution 4.0 International License (CCBY) which permits unrestricted use, distribution, and reproduction in any medium, provided the original author and source are credited.